ASUGI
Azienda Sanitaria Universitaria Giuliano Isontina
REGIONE AUTONOMA FRIULI VENEZIA GIULIA

L'assistenza e il monitoraggio in pneumologia interventistica

Dott. Mario Santagiuliana,
S.C. Pneumologia di Trieste – Direttore Prof.Marco Confalonieri,
Ospedale di Cattinara
Email: mario.santagiuliana@asuits.sanita.fvg.it

Cosa è la Pneumologia Interventistica?

Historical Perspectives of Bronchoscopy. Connecting the Dots

Tanmay S. Panchabhai and **Atul C. Mehta**
+ Author Affiliations

14.981 88

https://doi.org/10.1513/AnnalsATS.201502-089PS **PubMed:** 25965540

Received: February 14, 2015 Accepted: March 15, 2015

Un po' di storia...della broncologia...

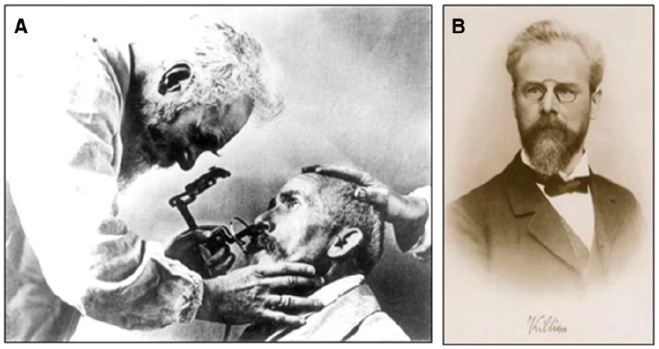

Figure 1. (*A*) Gustav Killian, the father of bronchoscopy, performing one of the very first bronchoscopies in a volunteer. (*B*) A portrait of Killian.

Nata nel 1895?



Figure 2. (*A* and *B*) Father of American bronchology, Chevalier Jackson, introduced the first illuminated rigid bronchoscope. (*C*) He designed and built endoscopes as well as accessories in his own tool room.



Figure 4. (*A*) Shigeto Ikeda, the innovator of the flexible bronchoscope, and (*B*) his first instrument.

Un salto nel 1968



Fig. 1 The EFER rigid bronchoscope

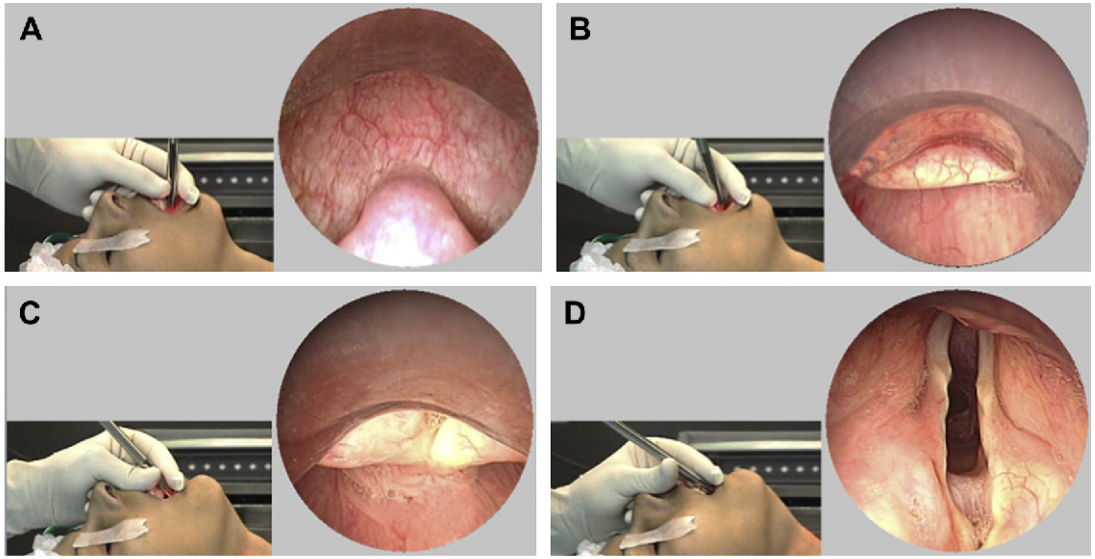

Ultrasound-guided fine needle aspiration

- Endobronchial ultrasound-guided fine needle aspiration (EBUS)
- Endoscopic ultrasound-guided fine needle aspiration (EUS)
- EUS radiale

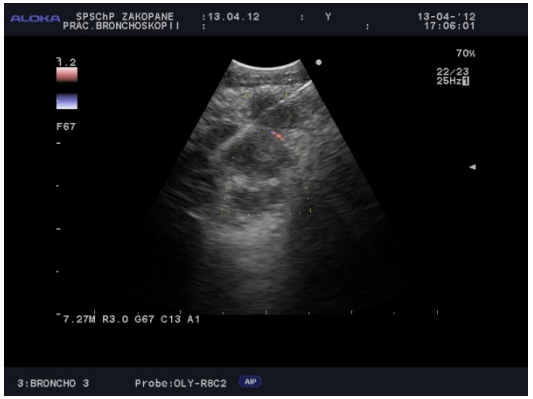

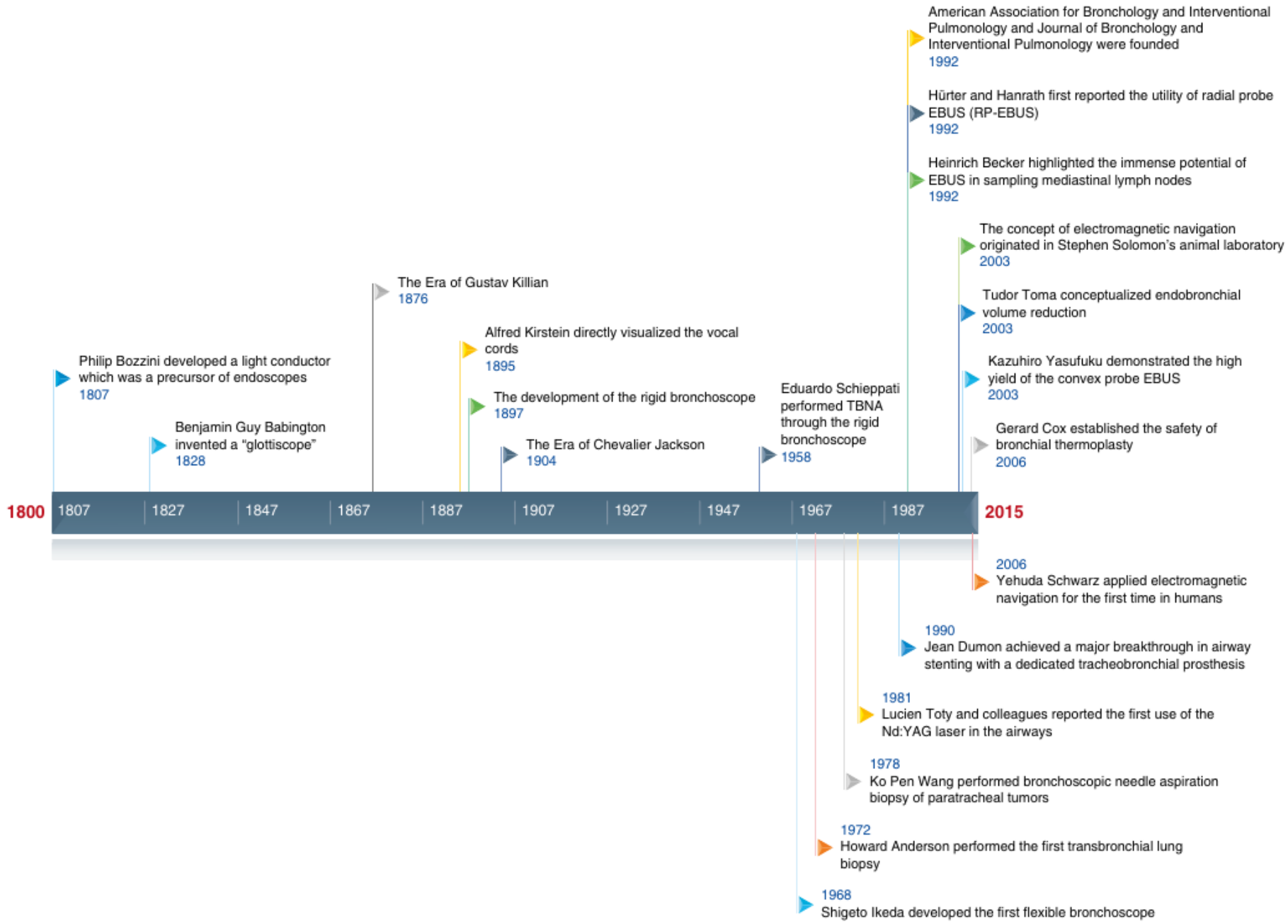

Figure 14. Historical timeline of major milestones in the field of bronchoscopy. EBUS = endobronchial ultrasound.

Ma non solo broncoscopia: La Pleura!!!

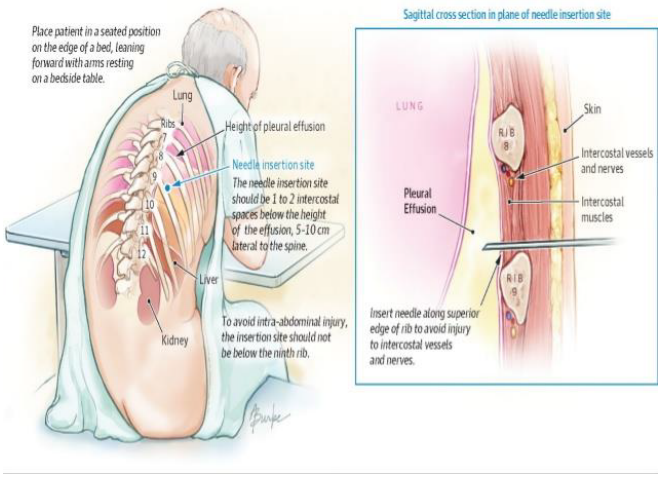

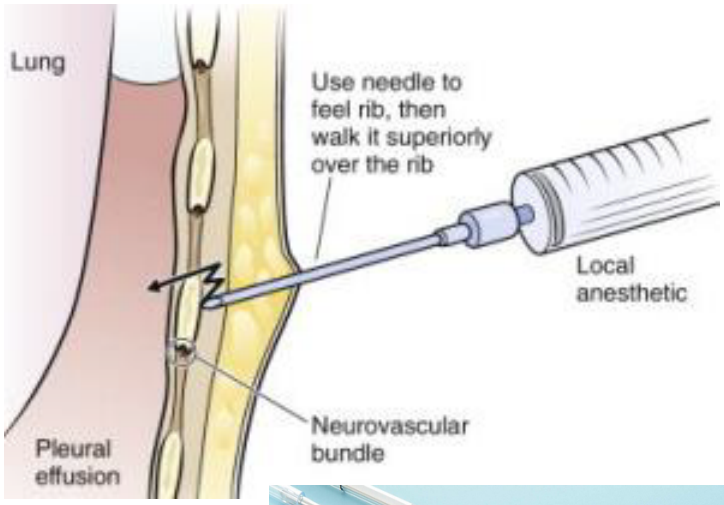

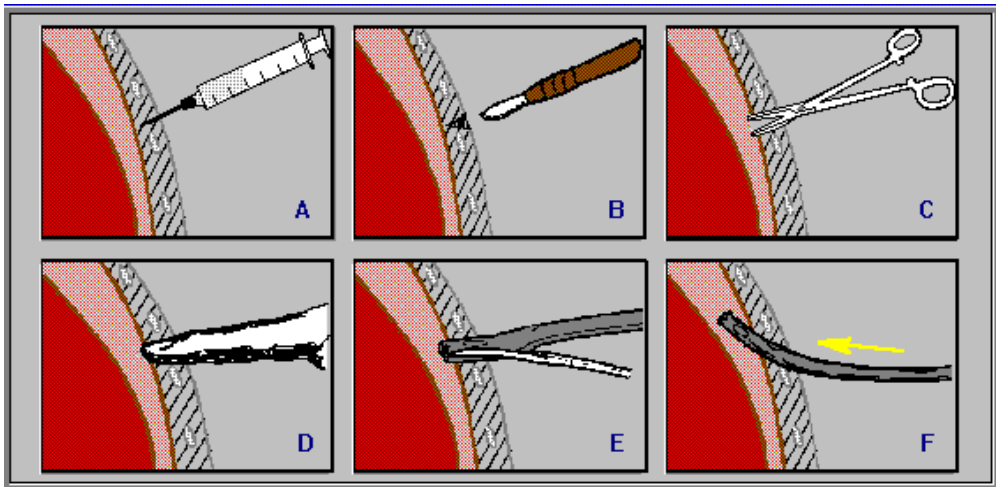

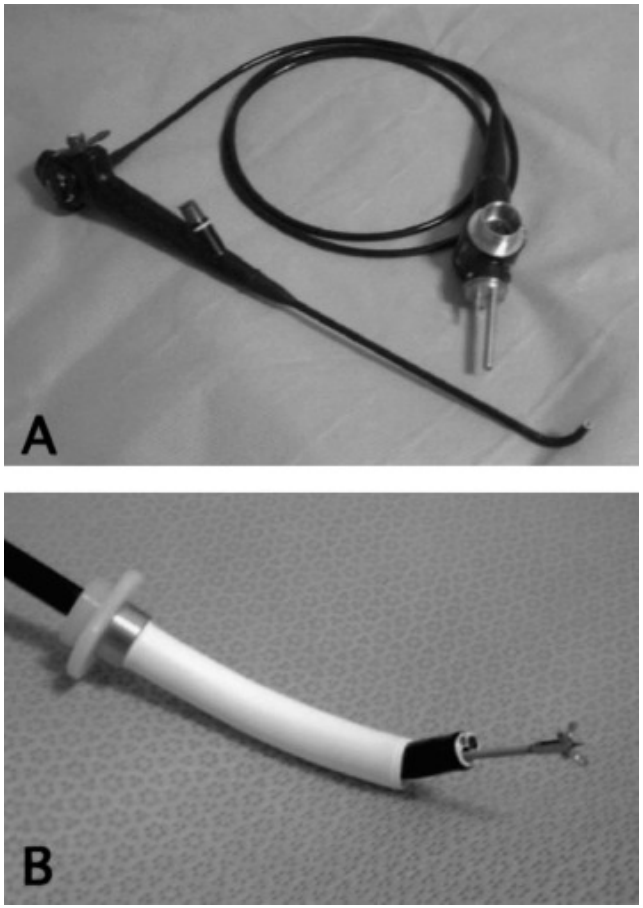

FIGURE 1. Standard equipment for thoracoscopy in pleural effusions.

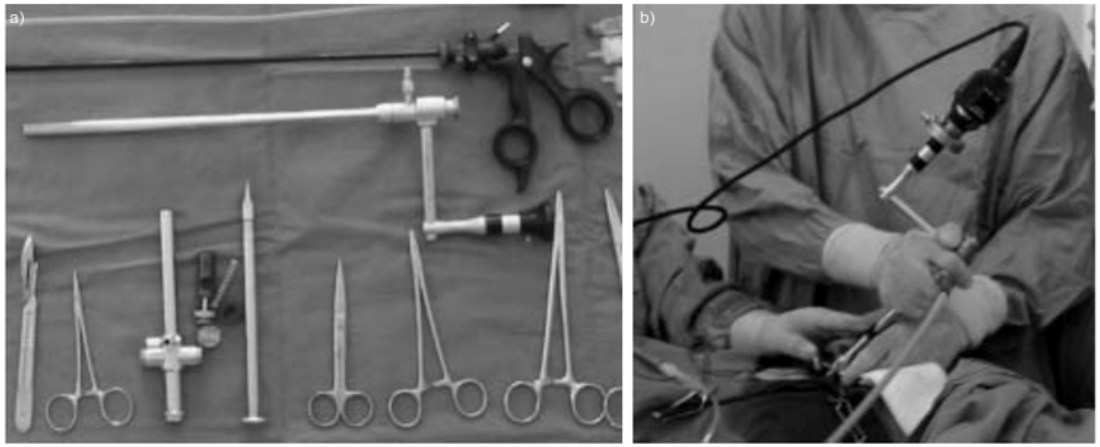

FIGURE 3. "Bayonet" thoracoscope (a) and in use (b), which allows large biopsies to be taken with a single port of entry.

Distanziatore per stereotassi

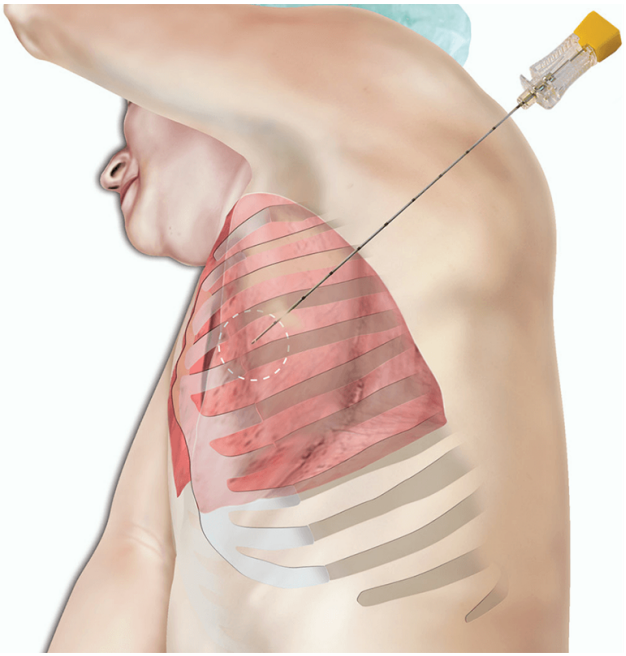

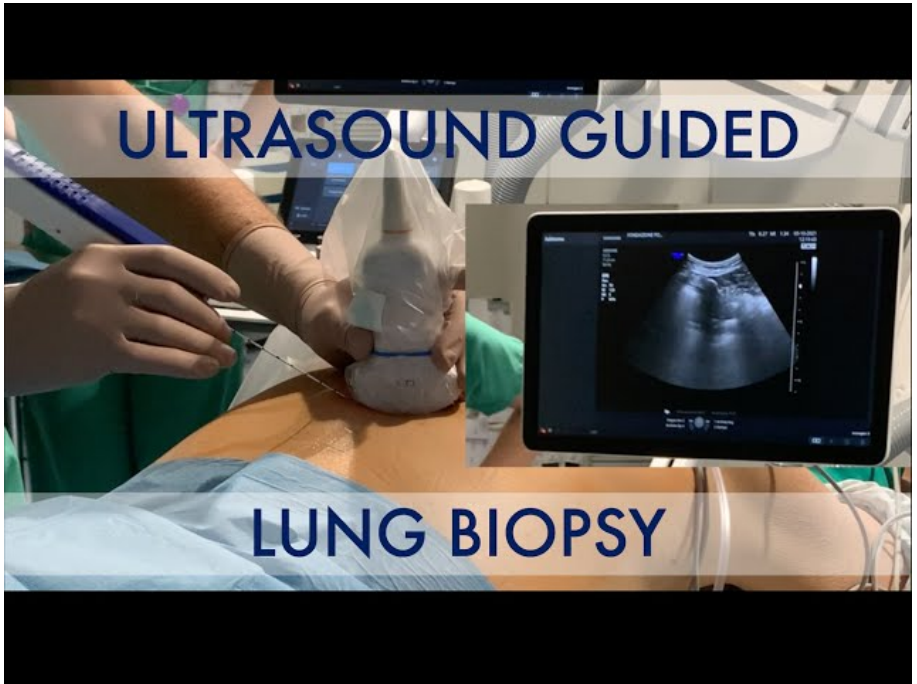
ULTRASOUND GUIDED
LUNG BIOPSY

Emodinamica polmonare

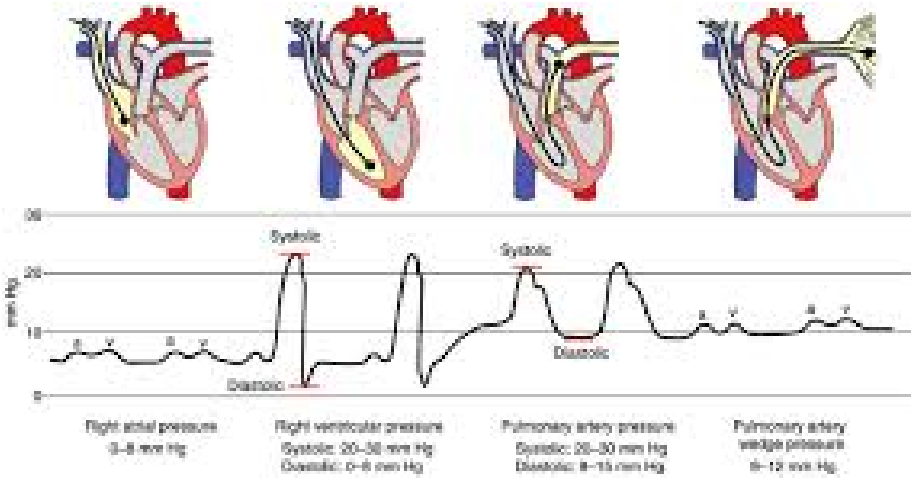

Figure 17-58 Normal values and wave configurations produced by the pulmonary artery catheter

Copyright © 2005 Lippincott Williams & Wilkins. Instructor's Resource CD-ROM to Accompany Critical Care Nursing: A Holistic Approach, eighth edition.

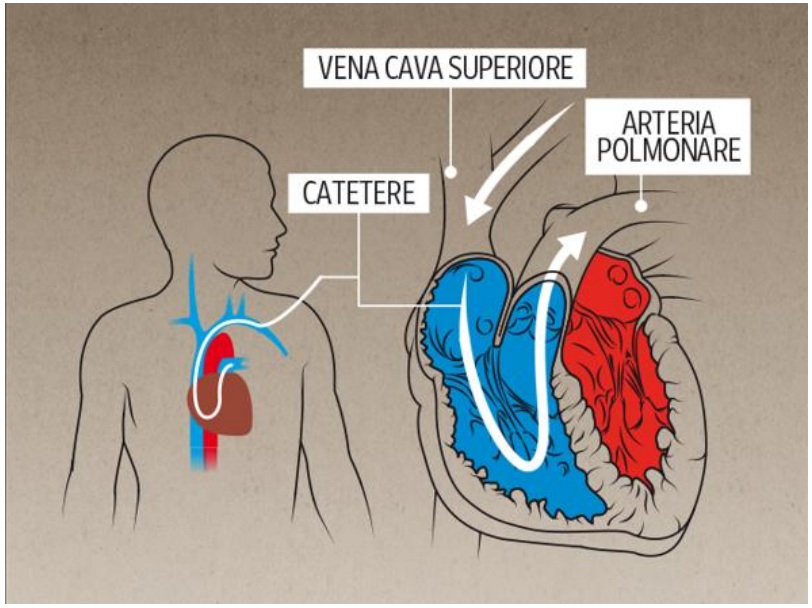

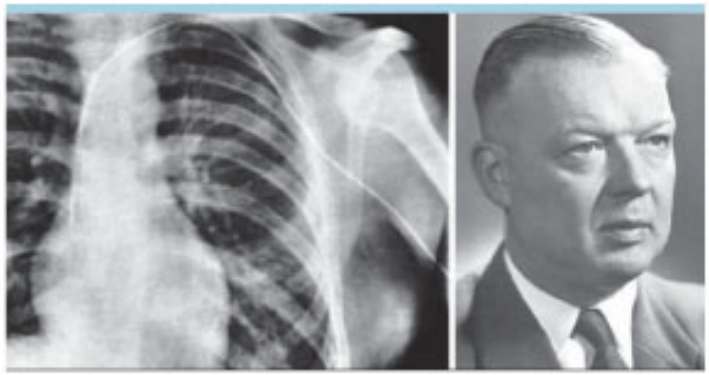

Figura 1. Foto di Werner Forssmann e della radiografia del suo torace durante il primo cateterismo cardiaco destro.

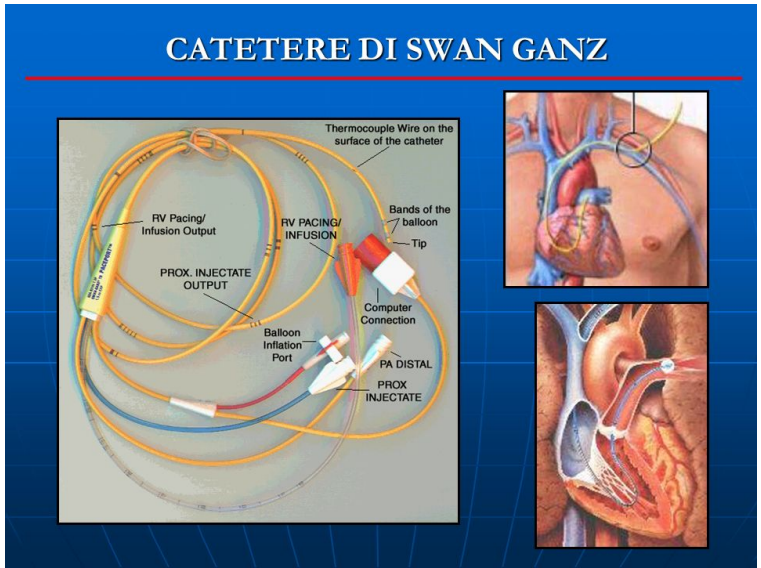

A che scopo?

Approccio pratico

Campionamenti non chirurgici?

Broncoscopico

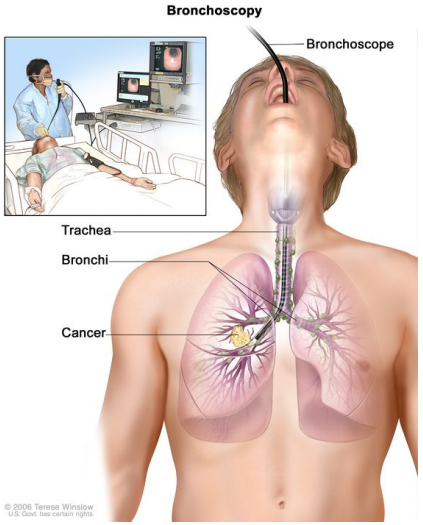

Percutaneo

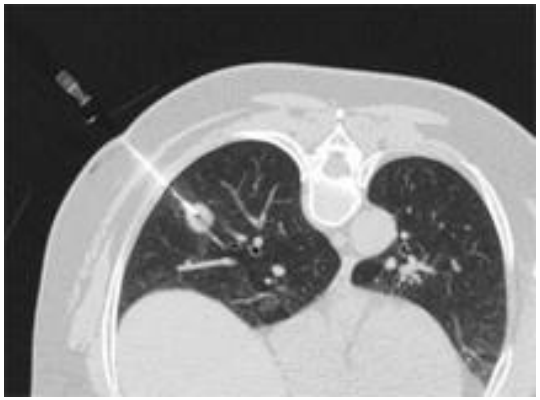

Studio di lesioni Endotoraciche

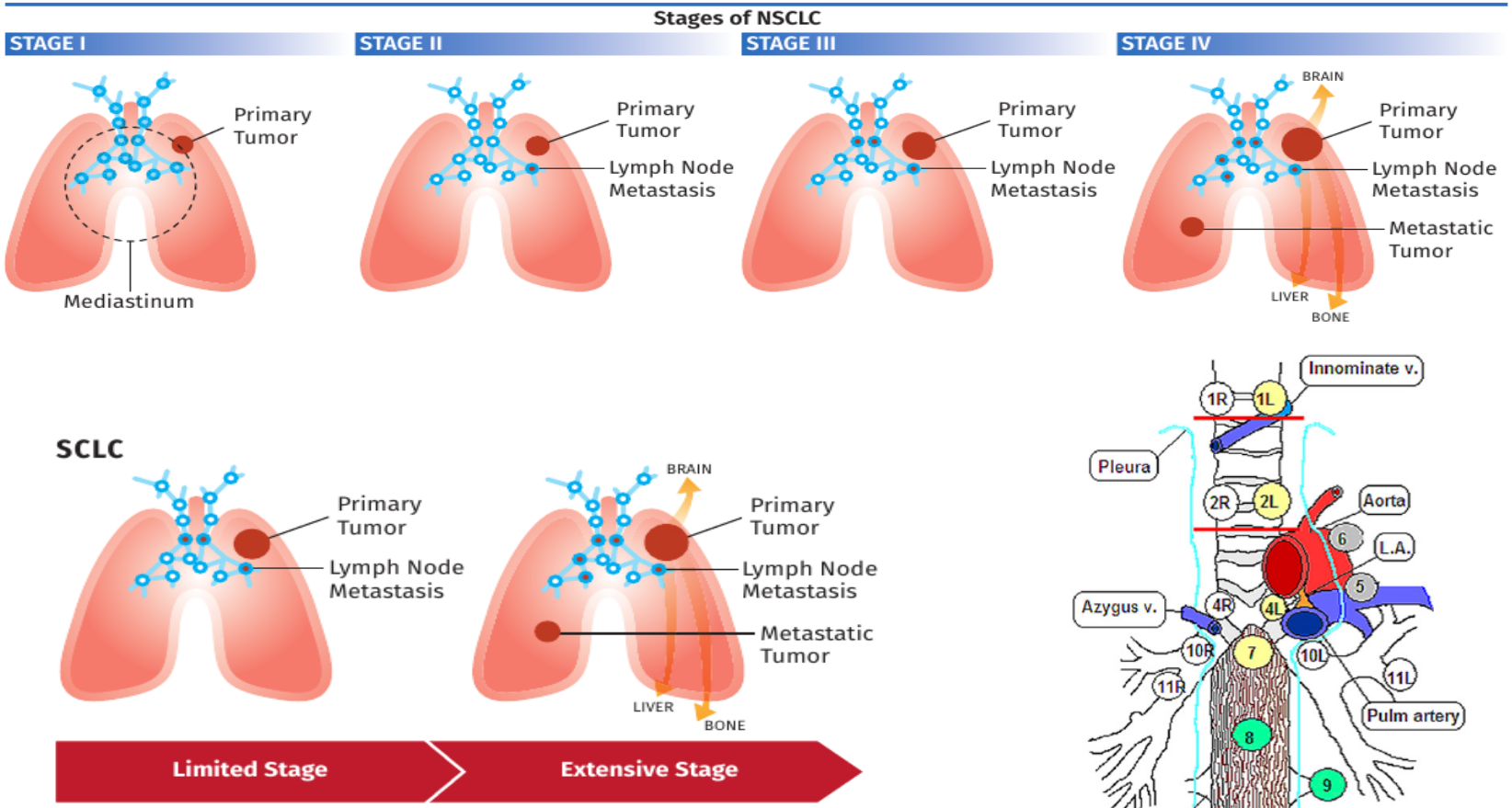

Am J Respir Crit Care Med Vol. 205, P17-P19, 2022
ATS Patient Education Series © 2022 American Thoracic Society
www.thoracic.org

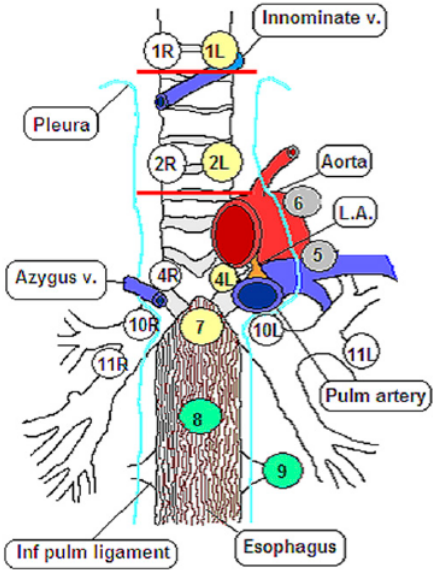

Figure 5. Regional lymph node stations for lung cancer staging accessible by EBUS (*white circles*) and EUS (*green circles*). *Yellow circles* = EBUS + EUS; *gray circles* = Nonaccessible by EBUS or EUS.

Tecniche di campionamento in broncoscopia

- Lavaggio bronchiale e BAL

- Brushing

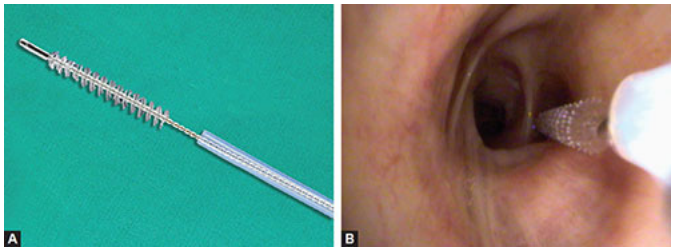

- Pinza bioptica

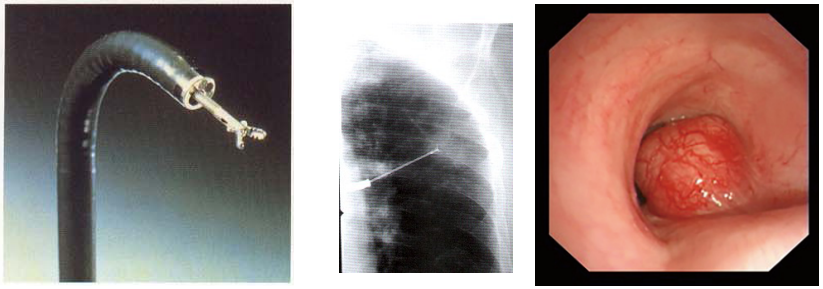

- Agoaspirato

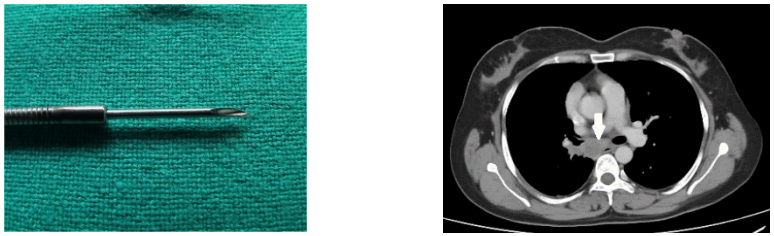

Neoformazione centrale endoscopicamente visibile

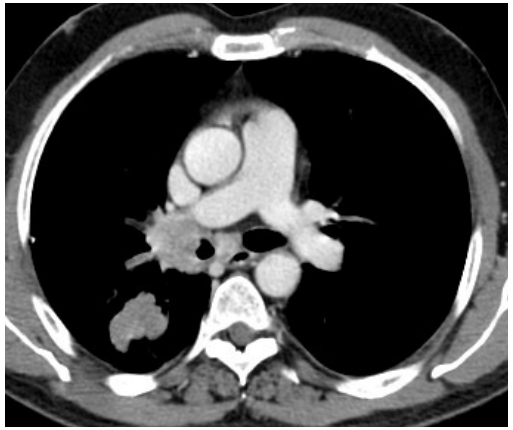

Agoaspirato

Biopsia

Brushing

Lavaggio

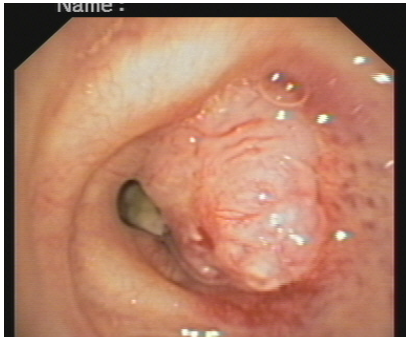

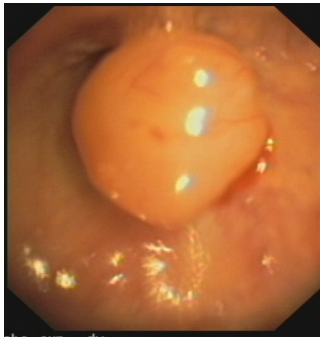

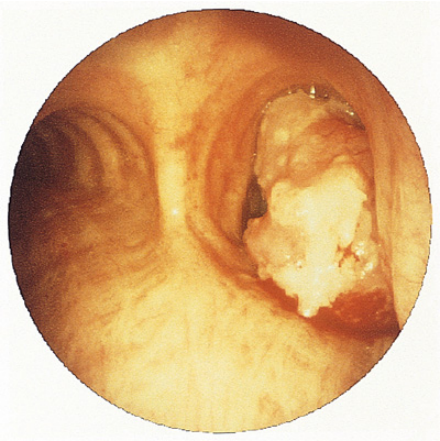

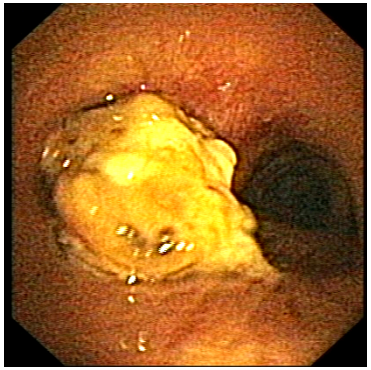

Fibroboncoscopia con guida fluoroscopica

L’addensamento polmonare periferico può essere campionato mediante fibrobroncoscopia con guida fluoroscopica, la resa migliore si ha utilizzando l’ago e la pinza in successione nella stessa seduta.

L’ago riesce a campionare anche le neoformazioni esterne all’albero tracheobronchiale non raggiunte dalla pinza.

Sensibilità 70% per lesioni periferiche > 2 cm.
Sensibilità 33% per lesioni periferiche < 2 cm.

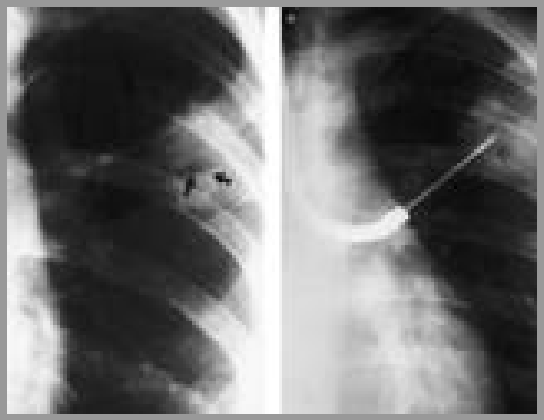

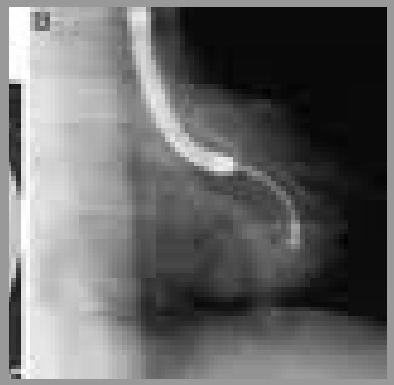

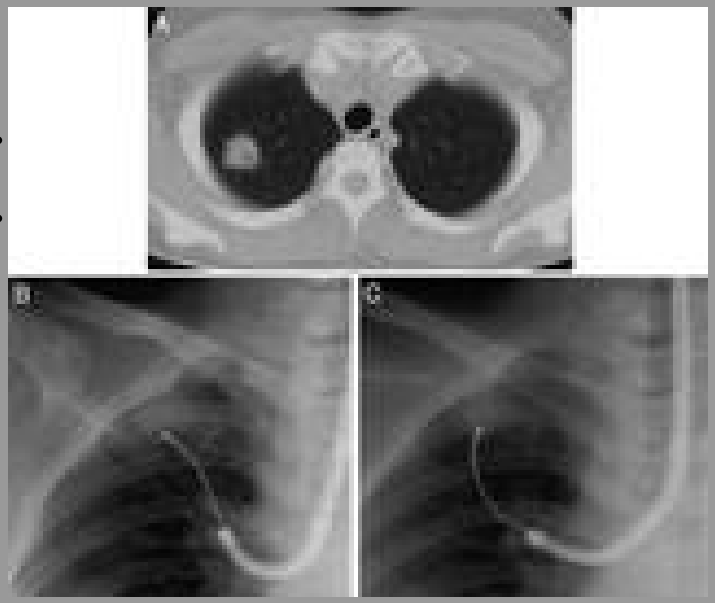

Schreiber G, McCrory DC. Performance characteristics of different modalities for diagnosis of suspected lung cancer: summary of published evidence. Chest. 2003;123:115S-128S.

CRIOSONDA

TBNA (Trans bronchial needle aspiration)

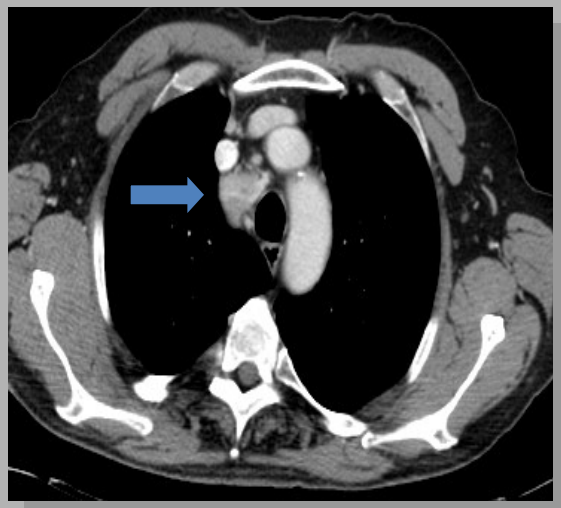

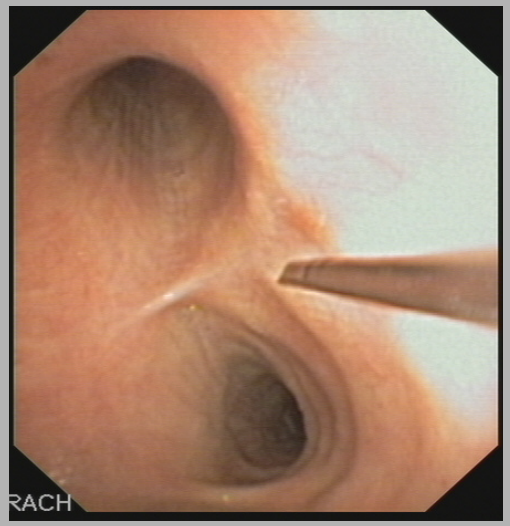

Campionamento di linfonodi/masse adiacenti alle vie aeree.

Detterbeck F, Jantz M, Wallace M, *et al.* Invasive mediastinal staging of lung cancer. ACCP evidence-based clinical practice guidelines. *Chest* 2007; 132: 202S.

NEOPLASIE

(review di 17 studi, 1339 pazienti)

Sensibilità 78%

Specificità 99%

Ma ha dei limiti...

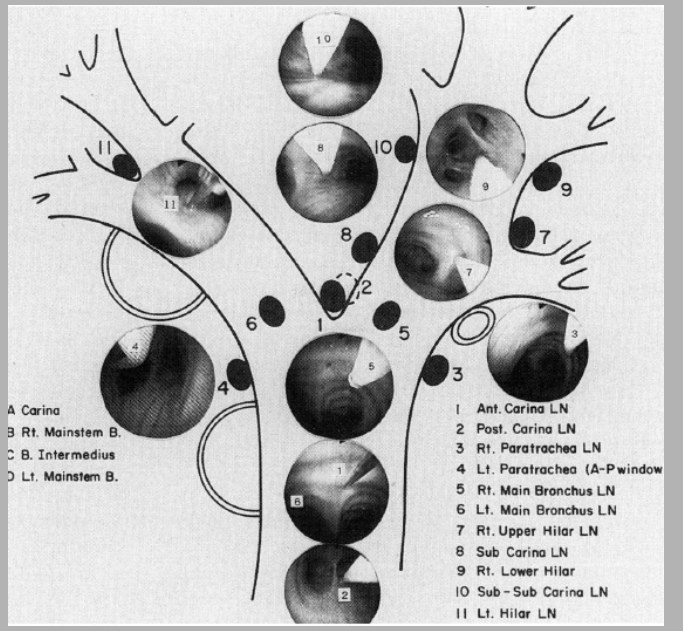
A Carina
B Rt. Mainstem B.
C B. Intermedius
D Lt. Mainstem B.
1 Ant. Carina LN
2 Post. Carina LN
3 Rt. Paratrachea LN
4 Lt. Paratrachea (A-P window
5 Rt. Main Bronchus LN
6 Lt. Main Bronchus LN
7 Rt. Upper Hilar LN
8 Sub Carina LN
9 Rt. Lower Hilar
10 Sub-Sub Carina LN
11 Lt. Hilar LN

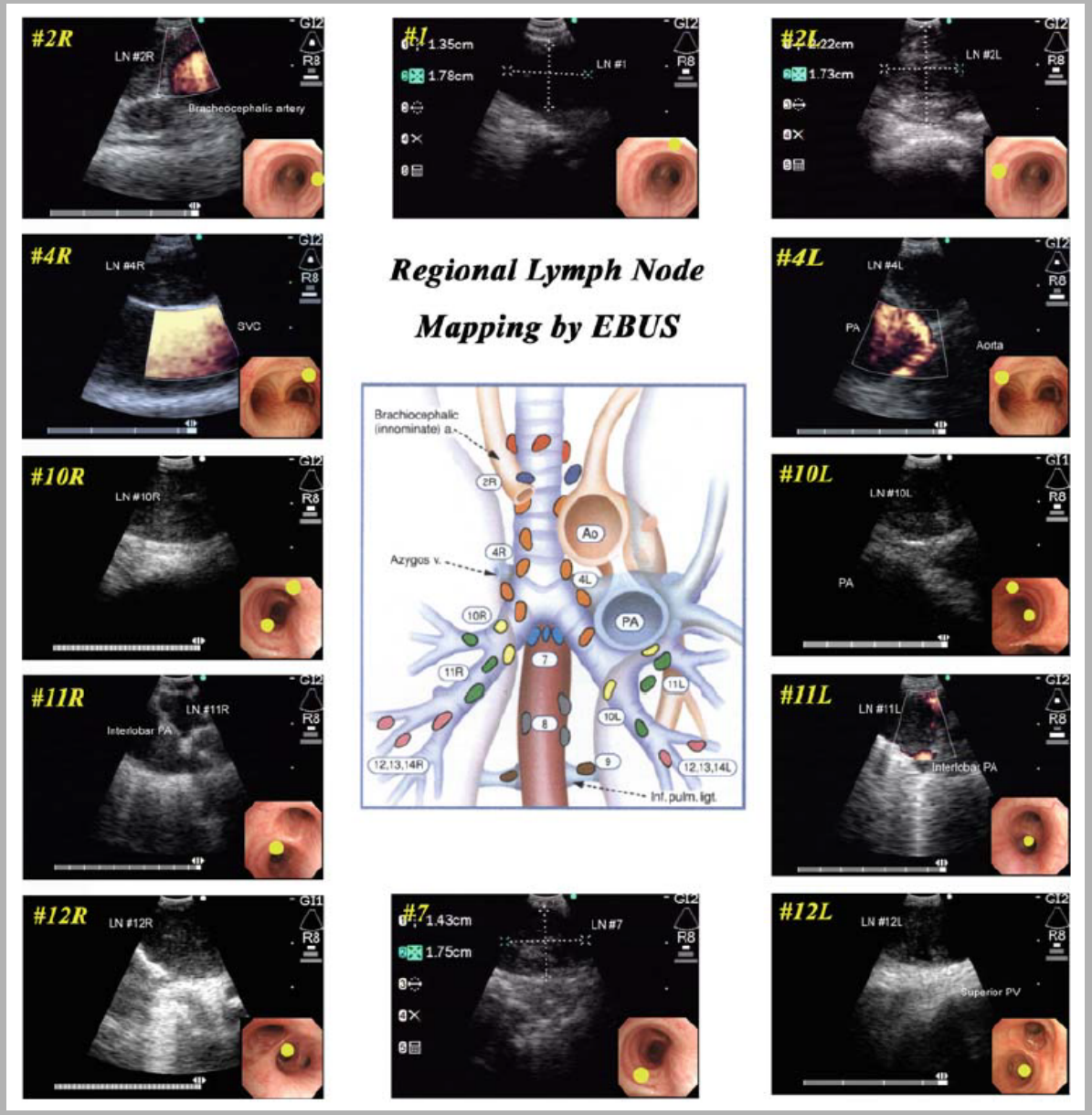
#2R
LN #2R
Brachiocephalic artery
#1
1.35cm
1.78cm
LN #1
#2L
1.73cm
LN #2L
#4R
LN #4R
SVC
Regional Lymph Node
Mapping by EBUS
#4L
LN #4L
PA
Aorta
#10R
LN #10R
Brachiocephalic (innominate) a.
Azygos v.
Ao
PA
Inf. pulm. ligt.
#10L
LN #10L
PA
#11R
LN #11R
Interlobar PA
#11L
LN #11L
Interlobar PA
#12R
LN #12R
#7
1.43cm
1.75cm
LN #7
#12L
LN #12L
Superior PV

I tipi di aghi in EBUS



Single use adapter biopsy valve (MAJ-1414)

This adapter should be attached to the instrument channel port of the Endoscope, before the needle is inserted.





21- 22G needle is operator controlled

Review > J Thorac Dis. 2015 Oct;7(10):E439-58. doi: 10.3978/j.issn.2072-1439.2015.10.08.

Ultrasound techniques in the evaluation of the mediastinum, part 2: mediastinal lymph node anatomy and diagnostic reach of ultrasound techniques, clinical work up of neoplastic and inflammatory mediastinal lymphadenopathy using ultrasound techniques and how to learn mediastinal endosonography

Christian Jenssen [1], Jouke Tabe Annema [1], Paul Clementsen [1], Xin-Wu Cui [1], Mathias Maximilian Borst [1], Christoph Frank Dietrich [1]

Affiliations + expand

PMID: 26623120 PMCID: PMC4635272 DOI: 10.3978/j.issn.2072-1439.2015.10.08

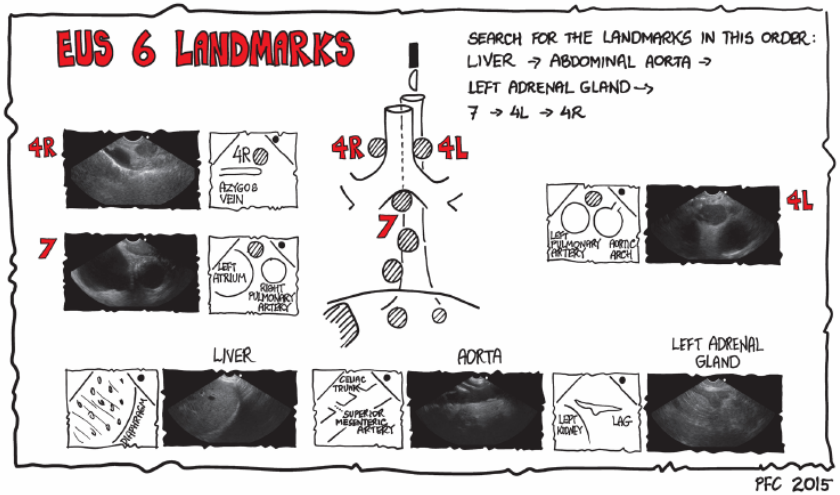

Figure 4 The six landmarks of endoscopic ultrasound (EUS) for lung cancer staging. Paul Clementsen is owner of the copyright.

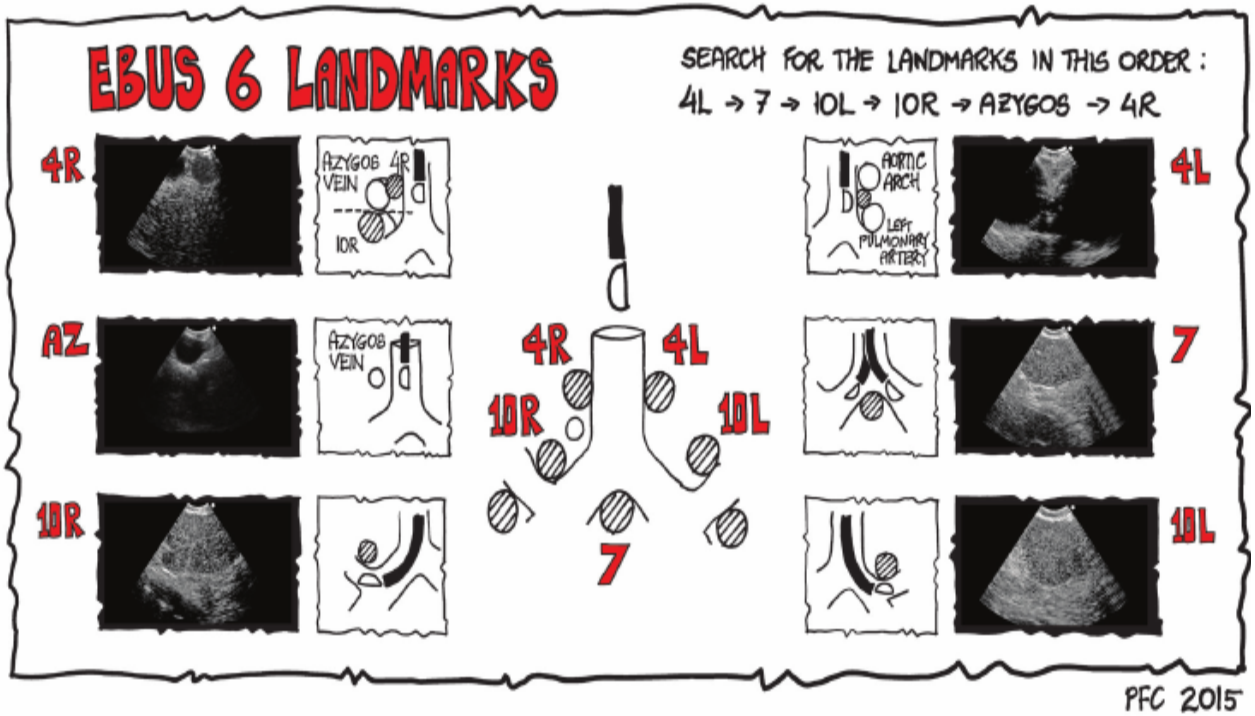

Figure 5 The six landmarks of endobronchial ultrasound (EBUS). Paul Clementsen is owner of the copyright.

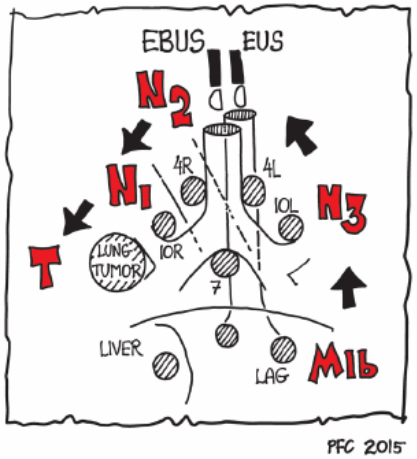

Figure 6 Systematic approach to endosonographic lung cancer staging. Paul Clementsen is owner of the copyright.

Pinze bioptiche in EBUS

RESEARCH ARTICLES | FEBRUARY 06 2023

Feasibility of Modified Endobronchial Ultrasound-Guided Intranodal Forceps Biopsy: A Retrospective Analysis

Subject Area: Pharmacology , Pneumology

Aya Konno-Yamamoto ; Yuji Matsumoto ; Tatsuya Imabayashi ; Midori Tanaka; Keigo Uchimura ; Takahiro Nakagomi; Komei Yanase; Clara So; Yuichiro Ohe; Takaaki Tsuchida

Respiration (2023) 102 (2): 143–153.
https://doi.org/10.1159/000528644 Article history
PubMed:36543151

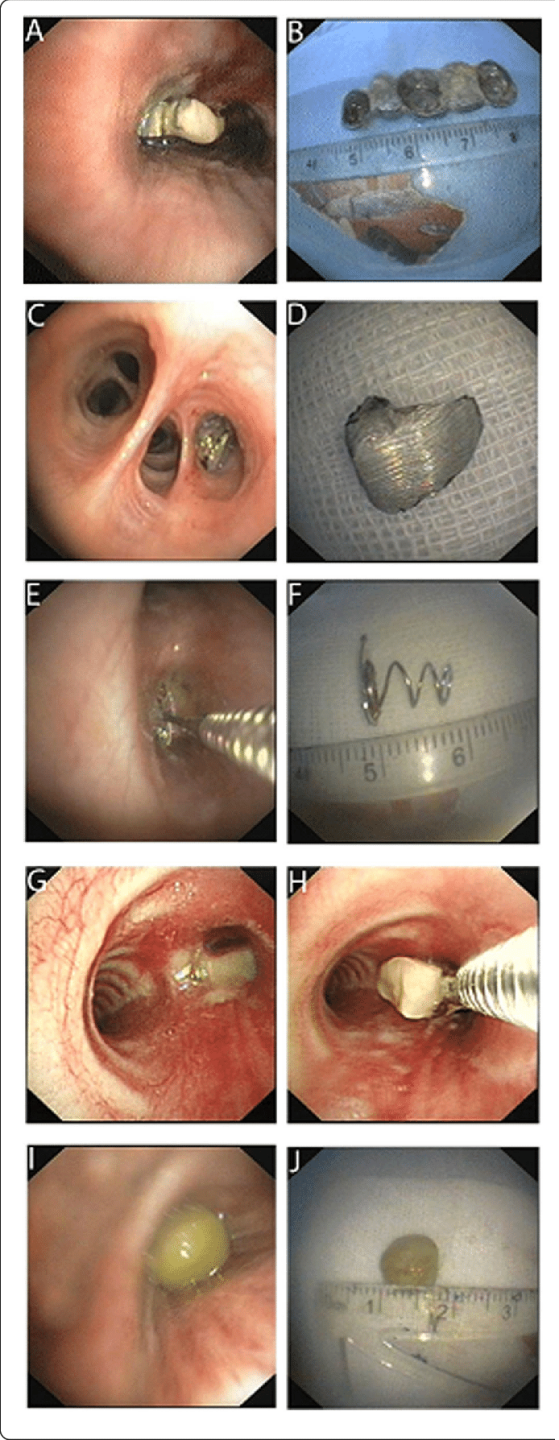

Corpi estranei???

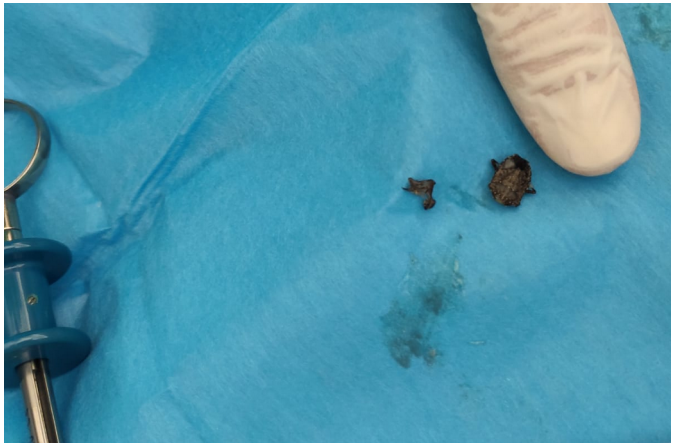

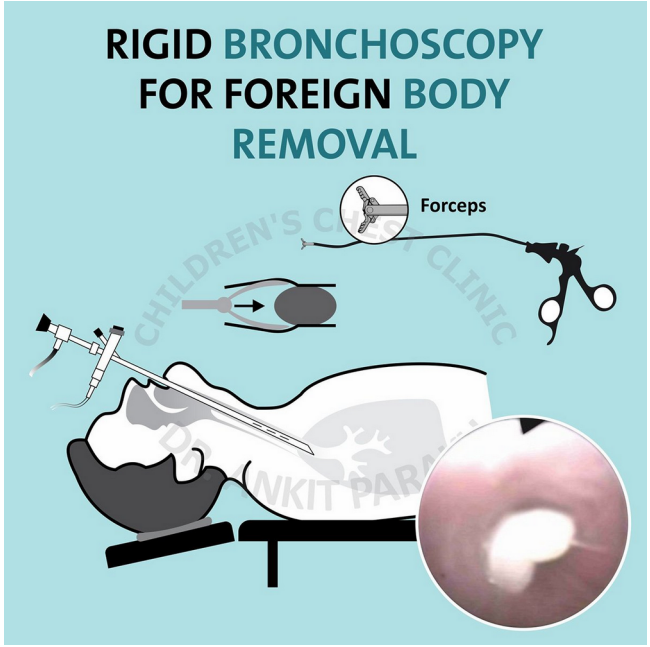

Patologie della pleura

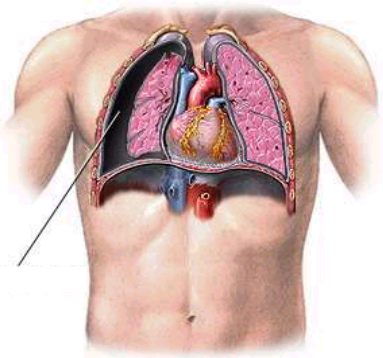

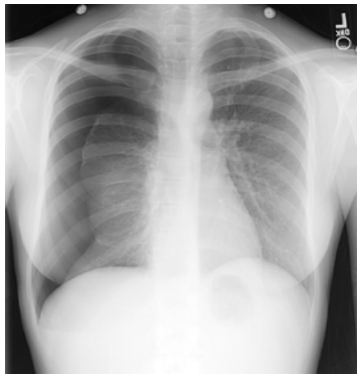

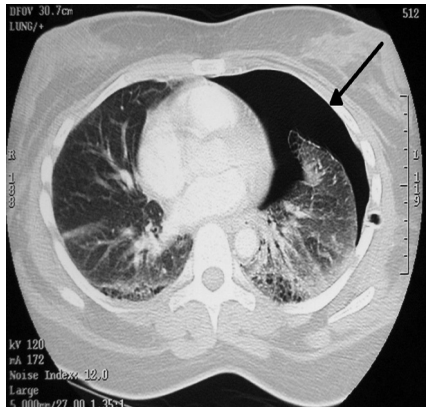

- “Aria”:
  - Pneumotorace
- “Liquidi”:
  - Versamento pleurico (eziologie multiple neoplastice, infettive, terzo spazio ecc.)
  - Empiema pleurico
  - Emotorace
- Combinazione dei due: Idropneumotorace

COMPLICANZE e COSTI

METODICA DIAGNOSTICA	MORTALITA'	COMPLICANZE MAGGIORI	COSTI (euro)
Fibrobroncoscopia	0,02%	0,12%	525
Agobiopsia polmonare TC guidata	0.02%	15% (PNX con drenaggio)	830
Mediastinoscopia	0,8%	2%	2477

Toloza EM et al. Invasive staging of NSCLC. Chest 2003.
Facciolongo, Gasparini et al. Incidence of complications in bronchoscopy.Monaldi Arch Chest Dis 2009.
Tomiyama N et al. CT-guided needle biopsy of lung lesions : A survey of severe complication Eur J Radiol 2006.
Assessorato alla Sanità della Regione Lazio: Finanziamento e definizione del sistema di remunerazione delle prestazioni ospedaliere e di assistenza specialistica ambulatoriale dei soggetti erogatori pubblici e privati. Bollettino ufficiale Regione Lazio 2007.

L’assistenza infermieristica

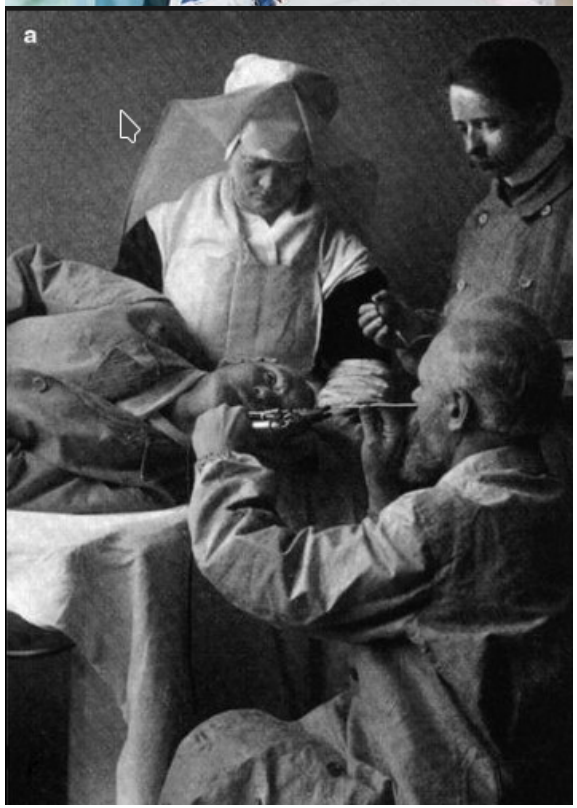

1. verifica del materiale;

2. preparazione del paziente;

3. collaborazione col medico e osservazione del paziente durante la procedura;

4. osservazione del paziente dopo la procedura;

5. controllo e codifica del materiale prelevato;

6. pulizia e disinfezione degli strumenti e degli accessori usati;

7. riordino e pulizia (es. del carrello endoscopico).

L’essenziale:
Il monitoraggio e...

Grazie per l’attenzione.